



FOCAL CEREBRAL AND CEREBELLAR ATROPHY IN A HUMAN SUBJECT DUE TO ORGANIC MERCURY COMPOUNDS

BY

DONALD HUNTER and DOROTHY S. RUSSELL

*From the Department for Research in Industrial Medicine (M.R.C.), and the Bernhard Baron
Institute of Pathology, the London Hospital*

Before the second world war a group of four patients suffering from profound neurological disturbances as a result of industrial exposure to methyl mercury compounds was studied by one of us. At the same time the effects of these compounds upon experimental rats and one monkey were assessed. A full account of this clinical and experimental work has been published (Hunter, Bomford, and Russell, 1940).

After an interval of 15 years one of these men (Case 4) has come to necropsy. Because it has afforded the first opportunity for a detailed histological study in this form of intoxication, and because the neuropathological changes proved both unexpected and intrinsically of considerable interest, we consider the case worthy of record.

Clinical

Recapitulation of Neurological Disturbance.—The subject, a man aged 23 when he first came under observation, had been exposed to dusts of methyl mercury phosphate and nitrate for a period of four months, beginning five months before admission to hospital. He had a squint and stuttered, both since childhood.

About April 13, 1937, he noticed numbness of his hands and forearms up to the elbow; also of his lips and of the centre of the tip of his tongue. When examined by Dr. S. P. Meadows a week later there was slight impairment of two-point discrimination (at 0.5 cm.) at the tips of his fingers. Apart from a concomitant convergent squint no further objective neurological signs were found; there was "no marked defect" in the visual fields (perimetry). Two days later (April 22) he spoke of having "pins and needles" in his hands, but said that this was improving. Dr. Meadows recorded a full neurological examination in which, again, impairment of two-point discrimination in the hands and fingers was alone found. Slight dysarthria was attributed to loss of all his teeth seven weeks previously.

After admission to The London Hospital (May 1) he was seen again by Dr. Meadows (May 3) who wrote: "Since I saw this patient 11 days ago there has been a

remarkable change in him." There was now a marked concentric constriction of the visual fields (see Fig. 5 of 1940 report). His speech had deteriorated and was stammering, and he was slightly deaf. Gait was unsteady, his hands shaky, and he had difficulty with buttons, though subjectively the numbness had gone. His tongue and lips, however, still felt numb. Objective neurological findings were: moderate bilateral ptosis; irregular fine nystagmus on deviation to right, left, and upwards; marked incoordination of movements in the upper limbs, without wasting or weakness, becoming worse with the eyes shut; difficulty in performing fine movements and rapid alternating movements; slight wandering of the fingers with the hands outstretched, and a tendency for the hands to drop with eyes shut. In the lower limbs there was no wasting or weakness; tone normal; incoordination and gross dysmetria, however, were obvious. Reflexes were brisk and equal in all limbs; diminished in the abdomen; both plantar reflexes were extensor. Response to cotton-wool, pin-prick, and vibration was everywhere normal; postural sensation was greatly impaired in the fingers, and slightly in the toes but not lost in the lips; stereognosis was impaired in the hands; two-point discrimination (at 1 cm.) was impaired at finger-tips. The patient showed marked ataxia with unsteady stance, overbalancing if the eyes were shut but just able to walk alone.

The further stages in this man's illness during his year's stay in hospital have already been fully recorded. It may be added that little change took place in his neurological state. Tremor was never observed. His ataxia remained gross and, when discharged a year later, he was quite helpless. He continued to attend the out-patient department for speech-therapy and physiotherapy and, in September, 1948, was readmitted to the wards for a month for reassessment. He was then found to be well orientated, his memory being good but dysphasia was gross. He had become blind in the left eye, the right showing severe constriction of the visual field as before. Nystagmus and bilateral ptosis persisted. The limbs when examined were affected as before. He was thus still grossly ataxic, helpless, unable to stand unaided or to walk without support. Attempts to feed himself proved "a long and messy undertaking". His blood pressure was 180/130 mm. Hg.

He was again admitted in September, 1950, being described then as intelligent, alert, and cooperative. His condition otherwise was unchanged. Blood pressure was 190/135 mm. Hg. Renal function tests gave normal results. He was finally admitted to Whipps Cross Hospital on December 14, 1952, with pneumonia and died there 14 days later.

Necropsy

An examination was made 22 hours after death by Dr. Keith Simpson, whose report is summarized as heart failure, myocardial fibrosis, and coronary atheroma. Back pressure congestion of liver, spleen, and kidneys; extensive ischaemic fibrosis of left ventricle of heart; no recent thrombus in atheromatous coronary arteries; chronic bronchitis with residual pneumonitis in lower half of lower lobe of left lung; emphysema of remainder of lungs, with infarcts in right upper lobe, and one at base of right lung. The remaining organs were of normal appearance. (Brain and spinal cord reserved.)

Histological Examination

The material received for examination included the brain, spinal cord, and portions of the sciatic and ulnar nerves, kidney, spleen, and a piece of heart muscle (left ventricle). All had been fixed in formaldehyde.

Macroscopic Examination of the Brain.—The leptomeninges appeared normal. The main cerebral arteries contained a few flecks of atheroma becoming confluent, but without stenosis, in the right vertebral artery. There was slight symmetrical convolutional atrophy at the frontal poles and severe about both calcarine fissures. The left optic nerve had been divided at the chiasm; the right appeared slightly flattened (measuring 0.6 by 0.2 cm.) but its cut surfaces appeared normal.




FIG. 1.—Coronal section of anterior part of left area striata to show gross atrophy. Weil-Davenport. $\times 2$ (approx.).

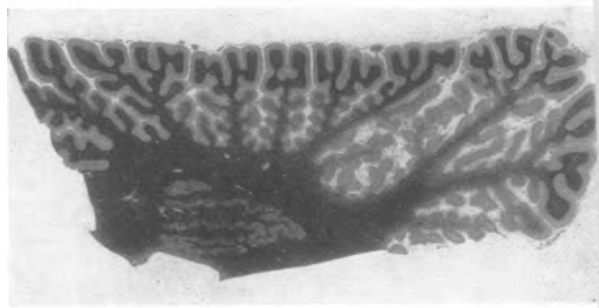
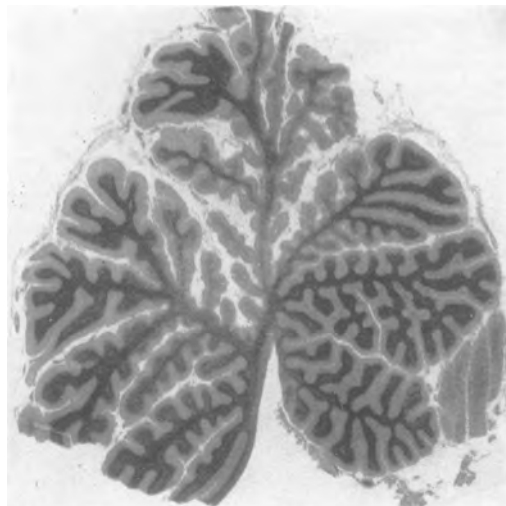


FIG. 2.—Lateral lobe of cerebellum. Note atrophy of folia in depths of sulci (right) with preservation of cortex at surface. Loyez' haematoxylin. $\times 2$ (approx.).

On section the occipital horns were considerably dilated, reaching to within 1.3 cm. of the poles. Convolutional atrophy was gross in the medial aspects of both occipital lobes, particularly about the anterior ends of the calcarine fissures (Fig. 1). This was greater on the left than the right, the thickness of the cerebral substance between the meninges and the ependyma being reduced to 0.4 cm. in places. This atrophy diminished towards the poles. The normal cortical striation of Gennari was absent. Occasional small foci of atrophy were also found in the cortex of the Rolandic area on both sides, and in the frontal and temporal lobes. No further changes were observed in the cerebrum or brain-stem.

In the cerebellum there was gross atrophy of the folia in the depths of the sulci in both lateral lobes, posterior to the primary sulcus (Fig. 2), but diminishing towards the mid-sagittal plane. A mid-sagittal section through the vermis displayed a similar atrophy in the declive, and through a segment of the adjacent culmen ascending from the inter-

FIG. 3.—Mid-sagittal section of vermis. Anterior end to left. Note atrophy in declive, extending in depths of vermis to adjacent lobules. Loyez' haematoxylin. $\times 2$ (approx.).



vening sulcus (Fig. 3). The flocculi were unaffected. The dentate nuclei appeared intact.

No changes were visible in the spinal cord.

Microscopic Examination of the Cerebrum.—The cortex of the area striata is grossly atrophied in both hemispheres. The loss of neurons here is very great in general but varies considerably in different fields. With higher magnification ($\frac{1}{8}$ in. objective) the most affected areas show fields where gliosis of varying density alone is present; in these the tissue sometimes contains small spaces (up to about 25μ in diameter) giving a spongy appearance.

The surviving neurons are small and, although some are well-preserved, many are shrunken and distorted. No "senile plaques" or neurofibrillary changes are present.

In frozen sections stained with Sudan III there are no fat-granule cells either in the cortex or white matter. Occasional angulated microglial cells in the cortex contain a little sudanophil material; some of these lie against the perivascular sheaths of the vessels. The adjacent leptomeninges and included blood-vessels are normal both here and in all other areas examined.

The subcortical white matter is greatly reduced, but no evidence of progressive degeneration was found either in the myelin or axis-cylinders and no fat-granule cells are present. The oligodendroglial cells are in stages of acute swelling. Transition from the atrophied to the non-atrophied gyri is rather abrupt; in the latter no changes were demonstrated. But comparison between the anterior and posterior parts of the area striata shows a decline in the

FIG. 4.—Greatly atrophied folium of lateral lobe to show destruction of granule cells, etc. Hortega's double impregnation. $\times 64$.

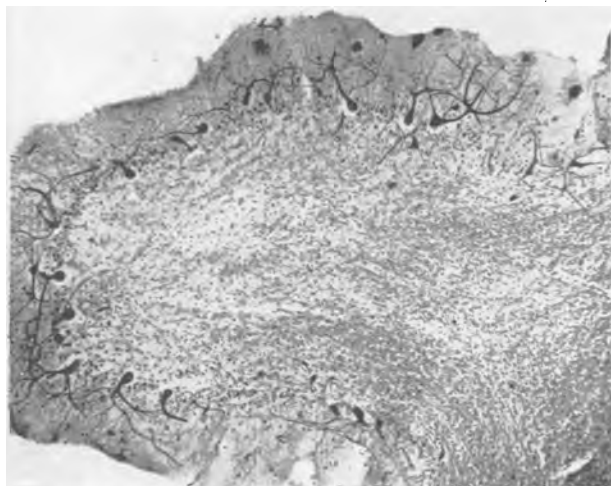


FIG. 5.—Cortex at summit of atrophied part of lateral lobe for comparison with Fig. 7. Hortega's double impregnation. $\times 125$.



severity of the atrophy, and destruction of neurons, as the occipital pole is approached.

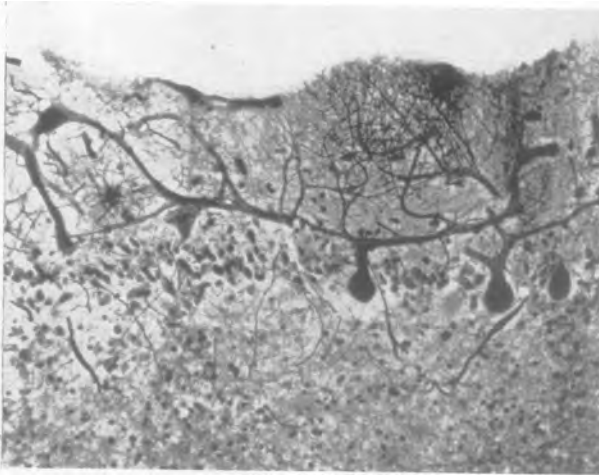
The optic radiation (left) is reduced in size but no further histological changes are present. The external geniculate body (left) appears normal. No changes were found in the optic chiasm and proximal end of the right optic nerve.

Foci of cortical atrophy, precisely similar to that seen in the visual cortex but more limited, were found in the left precentral gyrus, the right post-central and the left superior temporal gyrus. These foci affect the depths of the sulci rather than the summits and merge rather suddenly into the adjacent normal cortex.

The hypothalamus, basal ganglia, and brain-stem are not affected.

Microscopic Examination of the Cerebellum.—The cortical changes, in association with the atrophy observed macroscopically, are remarkable. In the granule-cell layer the loss of cells is profound while the Purkinje cells are in general spared (Fig. 4). The molecular layer is narrow. Proliferation of glial cells in the Purkinje-cell layer is associated with gliosis of the molecular layer. The changes are most advanced in the depths of the sulci while the cortex at the surface of the cerebellum is normal apart from a slight loss of granule cells (Fig. 5).

FIG. 6.—Atrophied cortex to show bushy area of Purkinje dendrites. Hortega's double impregnation. $\times 160$.



The morphology of the Purkinje cells is peculiar in many particulars. In some the cell-body lies at an abnormally high level in the molecular layer, or even close to the pia, and in these the main dendrites are oblique, horizontal, or directed towards the depths of the cortex. But the dendrites of those cells that are normally situated are also abnormally sinuous, in places excessively bushy (Fig. 6) and travel for considerable distances in a more or less horizontal direction, becoming intermingled with those of neighbouring cells (Fig. 7). Often they are coarse, tending particularly to be expanded at points of branching. A notable feature is the frequent development of terminal expansions with innumerable radiating spiky processes resembling a "witch's broom" (Figs. 8, 9). These were called "stellate bodies" by Cajal (1926). They are formed on dendrites at all levels in the molecular layer, occasionally amongst the cells of the Purkinje-cell layer, and even in the borders of the granular layer. Though they are only to be seen clearly in silver impregnations they correspond, in paraffin sections stained with aniline dyes, to eosinophil masses with indefinite borders which sometimes have a vacuolated or foamy centre and are pale, like cytoplasm, with other stains such as phosphotungstic acid, haematoxylin, and Nissl. The vacuoles appear empty in frozen sections stained with Sudan III. With silver (the double-impregnation of Hortega proved most satisfactory) they contain abundant interlacing fibrils, indistinguishable from neurofibrils, which continue into the

radiating processes. Approaching the more normal cortex these stellate bodies become fewer and their processes scantier.

Though the bodies of the Purkinje cells appear normal, including their content of Nissl bodies and neurofibrils, they are totally devoid of basket fibres in the most atrophied areas, and in this respect also there is a gradation to the normal cortex where these fibres are clearly demonstrated though perhaps fewer than normal. Where baskets are absent the cell-body sometimes bears a number of short, fine, lateral dendrites. Likewise climbing fibres are deficient in the atrophied cortex, with transitions to the more normal areas, and there is a concomitant loss of tangential nerve-fibres in the molecular layer.

Retraction-bulbs ("torpedoes") are numerous on the axons of Purkinje cells; the axon distal to this frequently bifurcates and the processes tend to loop back towards the molecular layer; their further course cannot be determined.

In the granule-cell layer there is, in addition to the great loss of these cells, a similar loss of the Golgi cells. The areas of greatest total denudation are the seat of a loose-textured gliosis. Fine and coarse axis-cylinders, traversing this layer, are well preserved. The terminations of mossy fibres can rarely be discerned in the areas of greatest loss.

In frozen sections stained by Sudan III there is no sudanophil material in the cerebellar cortex nor in the subjacent white matter. The microglia of the cortex appears inactive.

The white matter of the folia is diminished in bulk in proportion to the severity of the cortical changes; in the most affected areas there is some gliosis.

FIG. 7.—Atrophied cortex. Note loss of granule cells and numerous stellate bodies on Purkinje dendrites. Hortega's double impregnation. $\times 120$.



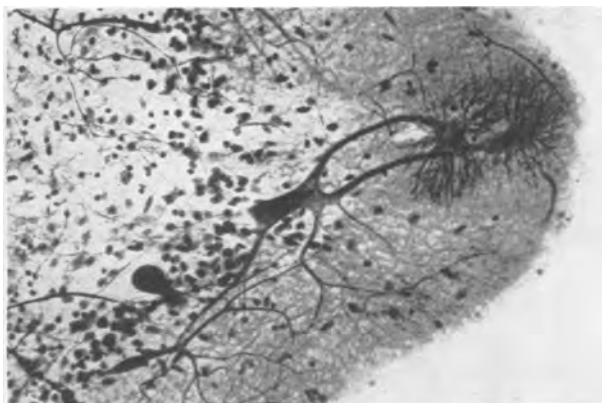


FIG. 8

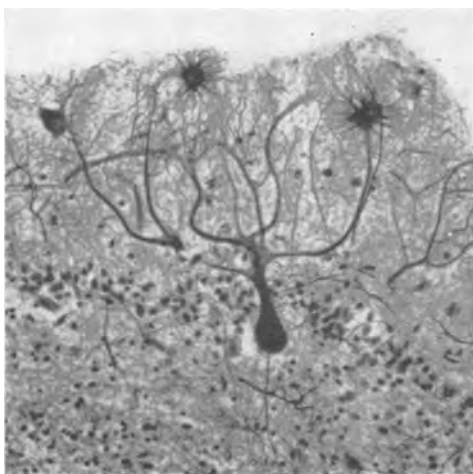


FIG. 9

FIG. 8.—Two stellate bodies on dendrites of a Purkinje cell. Hortege's double impregnation. $\times 180$.

FIG. 9.—Purkinje cell with stellate bodies. Note absence of basket fibres around cell body. Hortege's double impregnation. $\times 180$.

The central white matter is not appreciably reduced in bulk and appears normal microscopically. Likewise the dentate and associated roof-nuclei are not altered apart from variable degrees of chromatolysis and cell-shrinkage.

No abnormality was found in the cerebellar peduncles. The inferior olives are well preserved apart from some degree of chromatolysis and nuclear pyknosis in occasional neurons.

Microscopic Examination of Other Tissues.—The spinal cord, its nerve-roots, two posterior root ganglia (segments not identified), and the portions of sciatic and ulnar nerves are all normal.

In the kidney there is moderate focal ischaemic atrophy associated with fatty and hyaline degenera-

tion of cortical arterioles. Fatty degeneration affects many tubules, especially the loops of Henle in the medulla.

Gross confluent back-pressure congestion is seen in the liver.

In the heart there is dense subendocardial fibrosis replacing the muscle, becoming patchy or reticulated towards the epicardium.

Diffuse back-pressure congestion is seen in the spleen.

Discussion

The clinical disturbance in the case that has been described was principally neurological; it was rapidly progressive at the onset of his illness and thereafter static. The predominant features were a gross ataxia of general distribution combined with severe concentric constriction of the visual fields. During the last years of his life the blood pressure became elevated, and death was due to heart failure, doubtless attributable to myocardial infarction.

From the pathology it is clear that the neurological disturbances are referable to destruction of neurons in the central nervous system. The constriction of the visual fields is attributable to the gross atrophy of the area striata. It is noteworthy that this is greatest about the anterior ends of the calcarine fissures, with relative sparing near the occipital poles; this would explain the preservation of central vision which is located at the posterior extremity of the visual cortex.

The ataxia must be correlated with the gross alterations in the cerebellar cortex since the posterior columns of the spinal cord, and other pathways concerned with the cerebellar apparatus, were intact. The sparing of the palaeocerebellum is remarkable, especially in the vermis, and throws some light on the problem of functional localization in the cerebellar cortex. From his analysis of gun-shot wounds of the cerebellum Holmes (1917) found difficulty in assessing the significance of lesions of the vermis because in these the lateral lobes were also involved. But he concluded that greater degrees of difficulty in phonation, articulation, and postural maintenance of the head, neck, and trunk, were associated with injuries to the vermis. If this is true, the present case suggests that the declive is a key-point of functional representation in these respects. On the other hand Holmes observed gross disturbance of speech in seven cases sustaining bilateral lesions of the cerebellum. It is generally accepted that postural sense and the coordinated movement of the limbs are represented in the ipsilateral cerebellar hemisphere. From the present case it can be argued that the neo-, rather than the palaeo-cerebellum, is here

of importance. The absence of tremor is in agreement with the observation of intact dentate nuclei (Fulton, 1938). The early sensory loss in this man's illness was perhaps due to a transitory peripheral neuropathy, suggested by the regression of numbness in the upper limbs. The demonstrable atrophy in the post-central cortex is too slight to be significant.

Since it is argued that the damage to the brain in this case is directly referable to the toxic action of organic mercury compounds it is difficult to account for the localized nature of the degeneration; it can only be suggested that the affected areas were, for some reason, more susceptible. This suggestion, however, leaves unexplained the curious sparing of the folia at the surface of the cerebellum (Figs. 2, 3). This pattern is sometimes observed in cortical atrophy following severe anoxia, and may then be attributed to the remoter situation of the tissues in the depths of the sulci in relation to the arterial blood-supply. In the present case the degeneration and atrophy might have been expected to be the reverse of this, unless organic mercury compounds in the circulating blood enter into some chemical combination that produces an anoxic effect. We have no knowledge of such a possibility nor does it appear probable since it is rather the Purkinje cells of the cerebellum that are susceptible to anoxia.

The "stellate bodies" on the dendrites of the Purkinje cells, which are such a conspicuous feature in the present case, have been described in a subject aged 15 suffering from familial idiocy (Nageotte and Léon-Kindberg, 1910); in a woman of 65 with dementia praecox complicated by uraemia (Cajal, 1926); and in juvenile familial idiocy (Norman, 1940; Ule, 1952). These curious formations, and the other dendritic proliferations observed, are probably the regenerative response of the Purkinje cells to the loss of stimuli provided by climbing and basket fibres which, as described above, are lacking in these areas (see Ule for discussion and literature). The source of origin of the climbing fibres is controversial (Strong and Elwyn, 1943); the present case suggests that they arise from the granule-cell layer, but from which element therein cannot be determined.

The degeneration and atrophy of the granule-cell layer is thus the determining factor in the cytological changes that have taken place in the cerebellar cortex. The prime interest of the present case is that this, as far as we know, is the first occasion in which such a degeneration in man has been attributed to an exogenous toxin. In the human examples of granule-cell degeneration and atrophy the abnormality is usually manifest in infancy and may be familial. In animals there is evidence of a genetic

factor (e.g. in Hereford calves, Innes, Russell, and Wilsdon, 1940). In this connexion it is pertinent to recall the animal experiments which we have already described (1940). In our series of rats focal degeneration of the granule-cell layer was observed at 11 days and, in an animal kept alive for 12 weeks, this layer contained calcospherites. This degeneration however appeared later, and seemed of subsidiary importance to a profound degeneration of the posterior spinal roots, the peripheral nerves and, later, the posterior columns of the spinal cord. We therefore surmised, though erroneously, that the pattern of the degeneration in man proceeded along similar lines. But in the present case there is no evidence of degeneration either in the peripheral nerves or in the posterior columns.

We have here an excellent example of the fallacy incurred in the application of experimental work upon lower vertebrates to disease in man. The rhesus monkey, on the other hand, showed an intense degeneration of cortical neurons in the cerebrum, but the cerebellum was not obviously affected. In this animal, however, the course of the intoxication was very acute and it is possible that, with a longer period of survival, cerebellar cortical changes would have become demonstrable.

Our present case has shown that, in conformity with the rhesus monkey, the cerebral cortex was involved, though very unequally and with a particular impact upon the visual cortex. In the cortex of the neocerebellum the granule-cell layer was selectively involved, producing a picture already well recognized in certain juvenile cases with mental deficiency. From the clinical details of the case, and from the analogous findings in our previous experiments upon rats, it cannot be doubted that this cerebellar degeneration was an acquired lesion and that it was attributable to intoxication by organic mercury compounds.

Of the remaining three cases observed and recorded in our report (1940) Case 2, A.H., was last seen in May, 1954; his condition has remained unaltered since he was discharged from hospital. In Cases 1 and 2 the neurological disability was less severe; the subsequent course of these two patients is unknown.

Summary

The clinical history and ultimate pathological findings have been related in a man who suffered severe neurological disturbances from industrial exposure to methyl mercury compounds 15 years before death.

The generalized ataxia was referable to cerebellar cortical atrophy, selectively involving the granule-

cell layer of the neocerebellum, while the concentric constriction of the visual fields was correlated with bilateral cortical atrophy in the area striata.

While this form of cerebellar atrophy has been recognized in cases of juvenile familial idiocy, we believe the present case to be the first in which it can be attributed, as an acquired lesion, to an exogenous toxin.

We wish to express our thanks to Dr. S. P. Meadows for his clinical observations, to Dr. Keith Simpson for details of the necropsy and for preservation of material for histological examination, and to Dr. R. J. Calvert for his effective cooperation and clinical notes from

Whipps Cross Hospital. The photomicrographs were made by Mr. A. John King.

REFERENCES

- Cajal, S. R. (1926). *Trav. Lab. Rech. biol. Univ. Madr.*, 24, 181.
Fulton, J. F. (1938). *Physiology of the Nervous System*. Oxford Univ. Press, New York.
Holmes, G. (1917). *Brain*, 40, 461.
Hunter, D., Bomford, R. R., and Russell, D. S. (1940). *Quart. J. Med.*, 9, 193.
Innes, J. R. M., Russell, D. S., and Wilsdon, A. J. (1940). *J. Path. Bact.*, 50, 455.
Nageotte, J., and Léon-Kindberg, M. (1910). *Trav. Lab. Histol. Coll. Fr.*, 1908-9, p. 50.
Norman, R. M. (1940). *Brain*, 63, 365.
Strong, O. S., and Elwyn, A. (1943). *Human Neuroanatomy*. Williams and Wilkins, Baltimore.
Ule, G. (1952). *Dtsch. Z. Nervenheilk.*, 168, 195.